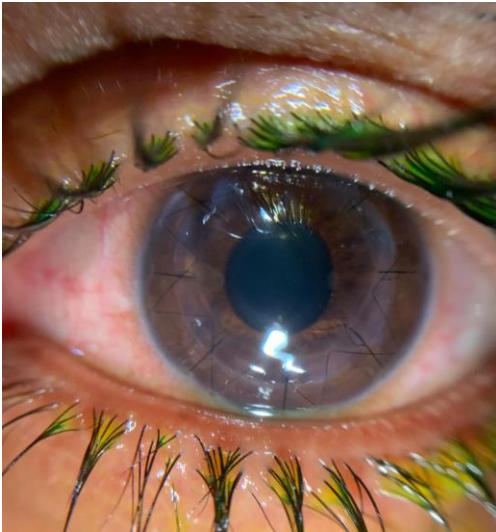
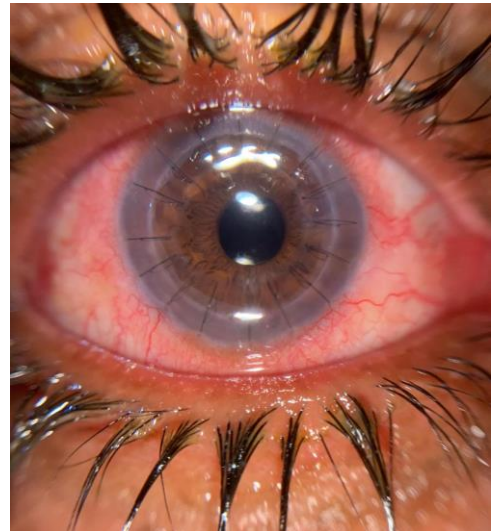

Case Study from Dr.Eissa

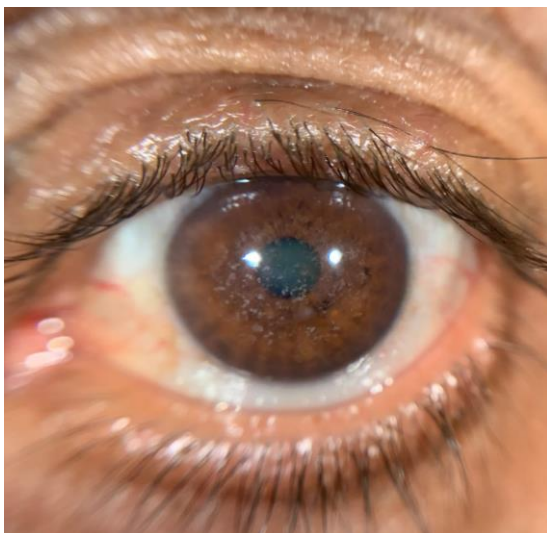
Dr. Hesham Mahmoud Eissa is a consultant ophthalmologist. He bought QuikVue at EOS (Egyptian Ophthalmic Congress) in March 2019. He is happy to share the following case he treated by using QuikVue to record the pathology progress.



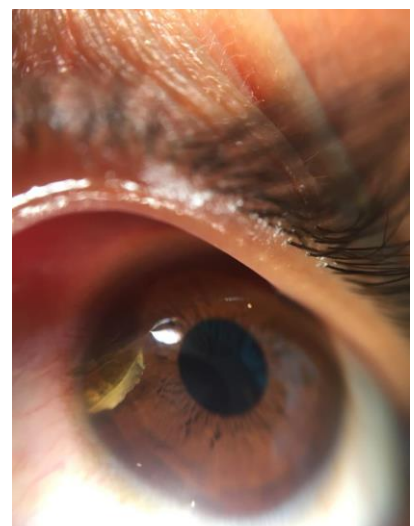
3 weeks post DALK surgery



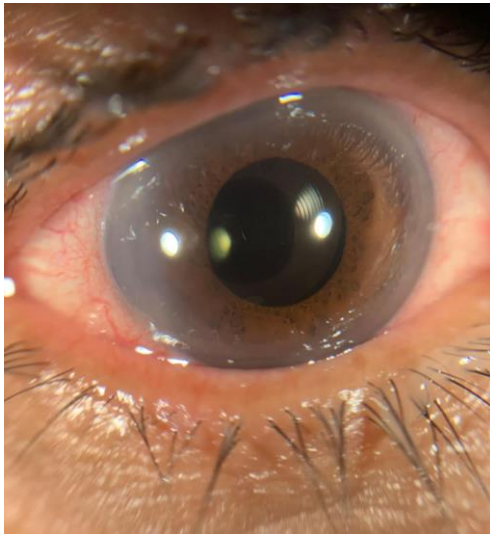
3 weeks post triple case(cataract removal, IOL implantation and keratoplasty)



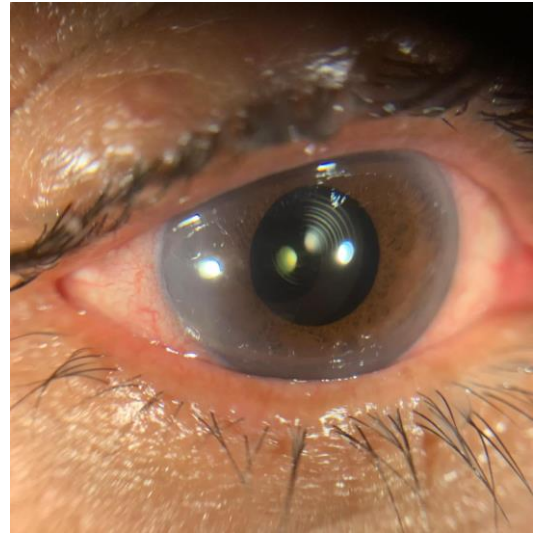
Corneal granular dystrophy type I



An intraocular foreign body in the AC through a semi self-sealed corneal wound.



a phaco patient had her surgery couple of hours and I implanted a trifocal lens



You can easily see the circles of the trifocal IOL on the optics

QuikVue® VPA-100

Smartphone Eye Imaging Adaptor
Eye Capture at Your Palm

- 10X magnification
- White/Cobalt blue illumination
- Fit on different phones
- Rechargeable with USB cable

